

Analysis of the Effect of Wearing Copper Oxide Impregnated Socks on *Tinea Pedis* Based on “Before and After” Pictures – A Statistical Follow-up Tool

Myriam Edith Gargiulo^{1*}, Adriana del Carmen Elías¹ and Gadi Borkow²

¹Universidad Nacional de Tucumán, San Miguel de Tucumán, Tucumán, Argentina; ²Cupron Scientific, Hasadnaot 10, Herzelia 46733, Israel

Abstract: The assessment of skin conditions by digital images as part of the evaluation of treatment efficacy is not widely used in podiatry. The main objective of our study was to evaluate quantitative measuring of *tinea pedis* (athlete’s foot) related medical endpoints via digital images of the affected feet areas before and after treatment as a supporting tool for podiatrists. In order to do so, we analyzed photographs taken of patients who had participated in a previous clinical study. During this already published study, the patient’s fungal feet infections were treated only by wearing of antifungal socks containing copper oxide. The efficacy of the treatment was then determined solely by clinical observations of the podiatrist. In the current study, we randomly and blindly analyzed 282 digital images of patient’s feet taken before and after using the socks in the pilot study. The affected feet areas, in which the *tinea pedis* infection was manifested by fissuring, scaling, erythema and/or vesicular eruptions, were determined before and after treatment by using ImageTool software. Statistical analysis of these determinations demonstrated a significant reduction in the severity of all 4 endpoints analyzed ($p < 0.05$). This is in accordance with the results described in the published study, further establishing that using socks containing copper oxide is efficacious in treating *tinea pedis*. The present study thus demonstrates that statistical analysis of quantitative data obtained from digital images taken during treatment of *tinea pedis* is feasible and may serve as a tool for podiatrists in monitoring treatment.

Keywords: Copper oxide, *Tinea pedis*, Antifungal socks, Image Tool.

INTRODUCTION

Fungal skin infection of the feet, *tinea pedis*, also known as athlete’s foot, is a major public health concern, affecting millions of people worldwide [1]. Feet are particularly prone to fungal infections as they are constantly in direct contact with the environment [2]. Approximately 15% of the population have a podiatric fungal infection at any given time and it is estimated that over 70% of the population have suffered at some point in their lives from *tinea pedis* [3]. There are no uniform global quantitative criteria defining the severity of *tinea pedis*, since in practice the diagnosis is often based on the specialist’s assessment of the clinical presentation of the infection.

Traditional pharmacological treatments of *tinea pedis* include a wide variety of antifungal creams, lotions and drugs. However, the development of resistance to conventional drugs, adverse effects related to some of these medications, the lack of patient’s treatment adherence, and the high reinfection rates, hinder the success of many antifungal treatments [4].

Copper is a trace element essential to humans, which plays a key role in many physiological processes in different tissues [5-7]. For example, copper has been shown to be

involved in angiogenesis and in wound healing [8-10]. Additionally, copper has very potent antibacterial, antifungal, and antiviral properties [11]. In contrast, human skin is not susceptible to copper, and the risks of adverse effects from dermal exposure to copper are extremely low [12]. Interestingly, even before the existence of microorganisms was known, and the indispensability of copper to normal metabolic functions was scientifically determined, the Egyptians, Greeks, Romans and Aztecs used copper to treat diseases [13]. Today, due to its biocidal intrinsic properties, copper is used in consumer, industrial and medical device products – e.g. anti-fouling paints, personal hygiene products, antimicrobial textiles and intra-uterine contraceptive devices [14-19].

Recently, a novel technology introducing copper oxide particles into polymeric materials, was developed (Fig. 1). Copper oxide is a nonsoluble form of copper, which slowly releases copper ions in the presence of moisture. Among the developments using this technology are wound dressings that enhance wound healing [8, 16]; antiviral respiratory masks that reduce the risk of infection [15]; acaricidal bedding products that kill dust mites [20]; pillowcases that enhance the wellbeing of the skin [21]; and in direct relevance to the current study, socks that protect from *tinea pedis* [14, 22-24]. These socks possess anti-fungal and anti-bacterial properties, and do not cause skin sensitization or irritation [14, 22-24].

To examine the efficacy of socks containing copper oxide in treating *tinea pedis*, a pilot study was carried out

*Address correspondence to this author at the B° 200 viviendas. Mz F Casa 5. (4000). Tucumán, Argentina; Tel: 54-92-4284395; Fax: 54-381-4223215; E-mail: megargiulo@fbqf.unt.edu.ar




Fig. (1). Scanning electronic microscope picture of copper oxide impregnated polyester yarn used in the socks.

Table 1. Endpoints Definitions

Endpoints Studied	Definition
Scaling	Peeling of the outer layers of the skin
Erythema	Redness of the skin due to increased blood supply
Fissures	Cracks in the skin
Vesicular eruptions	Itchy blisters on the soles and sides of feet

between September 2004 and January 2005 [23]. Fifty-six patients (17 women and 39 men), between 21 to 85 years of age, of which 21 were diabetics, and diagnosed with *tinea pedis*, were recruited. Six months before the study began and during the study, the patients did not receive any oral or topical antifungal medication. At the beginning of the study digital images were taken of the infected feet areas. Each patient received socks impregnated with copper oxide, and the patients were required to wear only these socks throughout the study, and not use any other medication for their feet infections. Patients were examined at the beginning of the study and at least twice subsequently - after 8 to 10 days and after 21 to 44 days. Scaling, erythema, vesicular eruptions, fissures and itching or burning were categorized as "improved" or "solved" according to the medical examination conducted by the podiatrist (with more than 20 years of clinical experience). Digital images of the feet were also taken during these examinations. The conclusion of the pilot study was that using copper oxide impregnated socks resulted in significant improvement or resolution of the *tinea pedis* infections in all 56 examined patients.

The objectives of the current study are a) determining the efficacy of using copper oxide containing socks in treating *tinea pedis* based solely on the statistical analysis of quantitative data obtained from the digital images taken during the above described study; and b) examining if quantitatively measuring *tinea pedis* related medical endpoints via photographs of the affected areas before and after treatment can be a supporting tool for podiatrists.

EXPERIMENTAL

The design of this study was quasi-experimental. Five hundred and ninety five photographs taken of the infected feet areas of patients suffering from acute or chronic *tinea pedis*, which participated in the published pilot study [23], were supplied by the pilot study specialist (Dr. R. Zatcoff). The specialist also provided the individual patient records. In

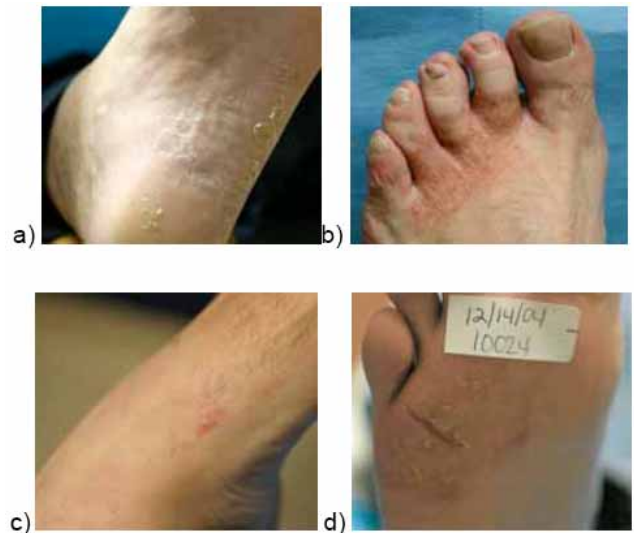

Fig. (2). Representative picture of a) scaling, b) erythema c) vesicular eruptions, and d) fissures.

Table 2. Variables Determinations

Endpoint	Variable	Measurement as Detailed in Table Footnotes
Scaling	Present/Absent	1
	Area of scales	2
Erythema	Present/Absent	1
	Area of erythema	2
Fissures	Present/Absent	1
	Longitude of fissures	3
Vesicular eruptions	Present/Absent	1
	Area of vesicular eruptions	2

1. A value of "0" or "1" was given when the particular variable was absent or present, respectively.
2. The area was calculated as that of a closed polygon, measured in pixels².
3. The fissures severity was determined as the length of the fissure, measured in pixels

each of these records, based on his personal expert evaluation of athlete's foot, the specialist stated the presence or absence of the relevant medical endpoint(s), which characterized each patient before the commencement of the study. The four medical endpoints detailed in Table 1 were analyzed in the present study. Fig. (2) shows representative pictures of each of these endpoints.

The photographs were taken with a Cannon Rebel XTI Camera and a 50 mm Cannon Compact macro lens. The photographs were labeled only with the patient's identification number. The photographs were analyzed in a blind manner. In other words, during the image analysis no information regarding the gender, age, length of infection, or any other patient information, was considered. The measurements were made by using ImageTool software version 3.0. Table 2 summarizes how the various variables were evaluated.

The difference in pixels between the measurements taken of an area affected by a particular endpoint at the start of the treatment and the end of the treatment was defined as a

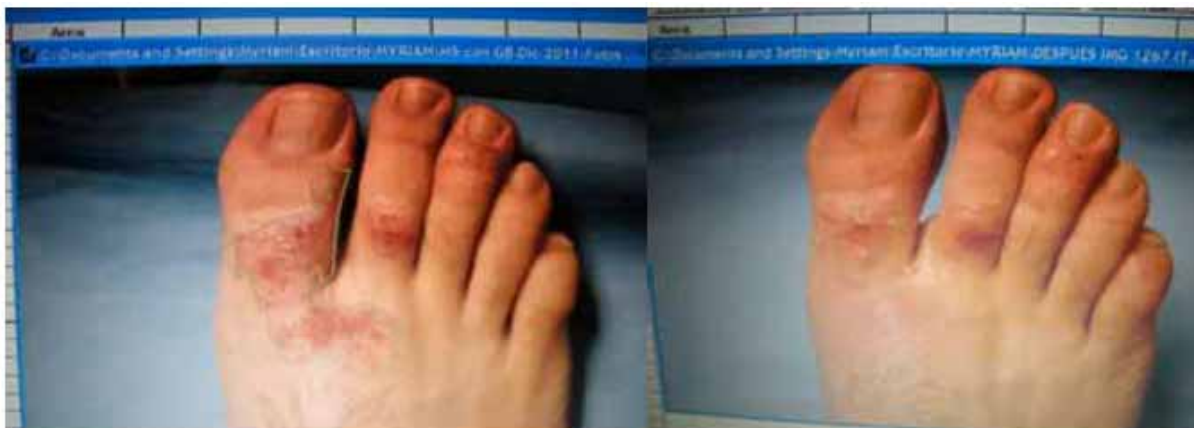

Fig. (3). Representative pictures showing how the affected areas were delimited from pictures taken before (left panel) and after (right panel) the socks were used in order to quantify the effect of the treatment.

Table 3. Recovery Grades (RG)

RI	RG Score
≤0.00	Negative
0.01 – 0.25	Low
0.26 – 0.50	Fair
0.51 – 0.75	Good
0.76 – 1.00	Excellent

"determination". Two photographs, of the same patient (one taken at the start of the treatment and one taken following treatment) showing the affected area from the same angle and with the same illumination, were selected. In some cases more than one area was affected by a particular endpoint in the foot, as seen in the photographs. In such cases, each distinct relevant area was measured separately and the sum of the areas was considered as the affected area. The images used for measuring a particular medical endpoint also served in many cases for measuring other medical endpoints in the same patient.

To measure the areas of the various variables (see footnote 2 to Table 2) the affected areas were delimited by using the option "area" of the software. Fig. (3) shows such an example. Each measurement was repeated three times, and the means (μ) and standard deviations (σ) were determined. A variability of less than 2% in the Coefficient of Variation Ratio (CVR) when averaging the three values was considered acceptable. The following formula was used to calculate the CVR:

$$CVR (\%) = (\mu / \sigma) \cdot 100$$

Table 4. Patients Descriptive Statistics

Gender # (%)		Age (Mean \pm s.d.)		Chronicity of Infection		
Female	Male	Female	Male	Years	Female # (%)	Male # (%)
17 (34)	33 (66)	56 \pm 14	63 \pm 17	<1	5 (29)	6 (19)
				1-5	2 (14)	2 (6)
				>5	10 (57)	25 (75)

The Recovery Index (RI) for each determination was calculated according to the following formula:

$$RI = \frac{\text{Mean affected area before treatment} - \text{Mean affected area after treatment}}{\text{Mean affected area before treatment}}$$

Based on the RI calculated, the Recovery Grade (RG) for each endpoint was determined according to the criteria specified in Table 3.

Statistical Analysis. The statistical significance of the RG for each one of the endpoints studied was determined by conducting a non-parametrical proportion test using the SPSS program (version 17.0). In order to conduct this test, each "low" or "fair" RG Score was referred to as "low improvement" and given the value of "0", and each "good" or "excellent" RG Score was referred to as "high improvement", and given the value of "1". A p value equal or less than 0.05 was considered statistically significant.

RESULTS

From the 595 photographs supplied by the pilot study specialist of the infected areas of the feet of 56 patients before and after treatment, only 282 photographs were used in this study. Three hundred and thirteen photographs could not be used due to the mismatched angle of photography or lightning conditions. The 282 photographs analyzed belonged to 50 out of the 56 patients that participated in the pilot study. As can be seen in Table 4, two thirds of these patients were males, most were elderly individuals and the vast majority (78%) suffered from chronic *tinea pedis* (more than 1 year), with no significant differences between genders.

Not all patients suffered from the same medical endpoints characterizing *tinea pedis*. Some expressed one or more signs related to the infection (e.g. fissuring and

Table 5. Medical Endpoints from which the 50 Patients Included in the Study Suffered from

Endpoint	Number of Patients	Percent Patients Suffering from a Given Endpoint
Scaling	50	100
Erythema	40	80
Fissures	31	62
Vesicular eruptions	16	32

Table 6. Number and Percent of Determinations Made for Each Endpoint

Endpoint	Number of Determinations	Percent Determinations that Could be Made for Each Endpoint
Scaling	165	60
Erythema	76	27
Fissures	24	9
Vesicular eruptions	12	4

erythema). As explained in the Experimental Section, the presence or absence of each medical endpoint was specified for each patient by the pilot trial specialist, as summarized in Table 5.

However, the particular specified endpoint detailed by the specialist was not always shown or could not always be measured in the supplied photographs. By contrast, in some photographs more than one medical endpoint could be measured. Table 6 summarizes the number of determinations performed for each endpoint from the 282 photographs analyzed using the program Image Tool [25].

The recovery grades, indicative of the treatment efficacies, are summarized in Table 7. In order to conduct a proportion test, the percentages of the “low” and “fair” were added and considered as “low improvement”; and the percentages of the “good” and “excellent” were added and considered as “high improvement”. The restructured data is also detailed in Table 7.

Table 8 summarizes the statistical significance of the RG for each one of the endpoints studied as determined by the

Table 7. Recovery Grade Scores

	Negative	Low	Fair	Good	Excellent
		<i>Low Improvement</i>		<i>High Improvement</i>	
Scaling	0	8.5	37.6	32.7	21.2
		46.1		53.9	
Erythema	0	39.5	50	3.9	6.6
		89.5		10.5	
Fissures	0	20.8	54.2	16.7	8.3
		75.0		25.0	
Vesicular eruptions	0	8.3	8.3	75	8.3
		16.6		83.4	

non-parametrical proportion test.

DISCUSSION

The present study analyzed the efficacy of treating *tinea pedis* by using copper oxide impregnated socks based solely on quantitative measurements performed on digital images taken of the affected skin areas before and after treatment. As far as we know, this is the first such study performed regarding *tinea pedis*.

Since the images taken by the podiatrist during the pilot study were not taken with the purpose of conducting the current study, no precautions were taken to assure that the images taken before and after treatment used the exact same illumination, background or photography angles. Had this been the case, we assume that a significantly larger number of determinations could have been performed based on the images supplied by the pilot study podiatrist. For example, it would have been possible to perform a significantly larger number of determinations than the 12 performed for the vesicular eruptions endpoint. The importance of using the same exact settings with respect to patient positioning, background, lighting and camera settings of photographs, taken before and after treatment in dermatological patients, has already been pointed out [26]. The current observations further emphasize the need to adhere to constant photography conditions, especially in cases where careful quantitative comparative data is sought, and particularly if this technique is adapted as a tool for podiatric follow-up and documentation.

Notoriously, an improvement was noted in all the endpoints examined in all the 277 determinations performed. This is in clear agreement with the results obtained in the pilot study, with the exception of one patient where, according to the reported medical assessment, the severity of scaling remained the same after treatment (i.e. 1.8% of the patients who suffered from scaling).

As determined by the proportion tests conducted, the use of the copper oxide containing socks resulted in statistically significant high improvement recovery grades in ~ 83%, 54%, 25% and 11% of the vesicular eruptions, scaling, fissures and erythema endpoints, respectively, within 13 days on average of using the socks. From these results, together with the observation that in all determinations there was some improvement, it may be clearly concluded, that the use of socks containing copper oxide results in clear

Table 8. Proportion test Analysis of the “High Improvement” Recovery Grades for Each Endpoint Studied

Endpoints	Estimated Percentage of Determinations with “High Improvement” RG	p-Value ^a
Scaling	53.9%	0.52
Erythema	10.5%	0.54
Fissures	25.0%	0.61
Vesicular Eruptions	83.4%	0.46

^awhen the p value is 0.05 or above it is accepted that the estimated percentage of determinations has a RG of high improvement.

reduction of *tinea pedis* related symptoms. This is in accordance with the results described in the pilot study, based on clinical observation of the patients [23]. As with any other treatment, the efficacy copper oxide impregnated socks depends on several factors, such as the patient’s adherence to using the socks, the active ingredient dosage, and the severity of the problem. Assuming high adherence of patients to treatment, it can be further assumed that the longer the socks are worn, the better the percentages of high improvement recovery grades. This was established in the pilot study and would need to be clearly established in a separate study by using photographs taken at different intervals following the commencement of treatment.

Several studies have been conducted to quantitatively assess skin conditions based on digital images [27]. In addition, appropriate software, often used in biology and dentistry, has been developed to measure areas and/or lengths in digital images [28]. Dermatological assessment from images may help increase the objectivity and reproducibility of the data evaluated by the specialist, but cannot replace expert clinical evaluation [29, 30]. The present study demonstrates that by using simple, widespread, and in many instances free available software, such as ImageTool, quantitative data can be compiled in order to monitor dermatological treatments, in this case related to *tinea pedis*. While this study suggests that image analysis might be used to complement the health care professional clinical assessment, it is unclear as to whether investing time and resources in such technology would benefit the patient or change treatment protocols over those prescribed by the health care worker without such technology. It may be that for routine follow-up, quantitatively acquiring the data with the existing software is too cumbersome and impractical. The use of more sophisticated and specialized software to compile quantitative data may make it easier to implement in a clinical setting. It is clear, however, that for investigational purposes, to demonstrate the efficacy of a given medication or treatment for *tinea pedis*, even use of the relatively simple software tools, such as ImageTool, can significantly strengthen the significance of the results and allow for clear statistical analyses and conclusions from such studies.

CONCLUSION

This study confirms previous observations regarding the efficacy of using socks containing copper oxide in treating *tinea pedis* related symptoms. The confirmation is based solely on the statistical analysis of quantitative data obtained from digital images taken before and after treatment. This study supports the notion that quantitatively measuring *tinea pedis* related medical endpoints via photographs of the

affected areas before and after treatment can be a supporting tool for podiatrists. The proposed technique allows obtaining meaningful reliable quantitative data, which may be statistically analyzed and used as a simple tool for monitoring treatment.

CONFLICT OF INTEREST

None declared.

ACKNOWLEDGEMENT

We thank Dr. R. Zatzoff for supplying the photographs that enabled us to conduct this study.

REFERENCES

- [1] Kumar V, Tilak R, Prakash P, Nigam C, Gupta R. *Tinea pedis* - an update. *Asian J Med Sci* 2011; 2: 134-8.
- [2] Dahdah MJ, Scher RK. Dermatophytes. *Curr Fungal Infect Rep* 2008; 2: 81-6.
- [3] Weeks J, Moser SA, Elewski BE. Superficial cutaneous fungal infections. In: Dismukes WE, Pappas PG, Sobel JD, Eds. *Clinical mycology*. Madison Avenue, NY: Oxford University Press 2003; pp. 367-89.
- [4] Gupta G, Malfet P, Kress DW, Sergeant A. Adherence to topical dermatological therapy: lessons from oral drug treatment. *Br J Dermatol* 2009; 161: 221-7.
- [5] Borkow G, Gabbay J, Zatzoff RC. Could chronic wounds not heal due to too low local copper levels? *Med Hypotheses* 2008; 70: 610-3.
- [6] Pickart L. The human tri-peptide GHK and tissue remodeling. *J Biomater Sci Polym Ed* 2008; 19: 969-88.
- [7] Uauy R, Olivares M, Gonzalez M. Essentiality of copper in humans. *Am J Clin Nutr* 1998; 67: 952S-9.
- [8] Borkow G, Gabbay J, Dardik R, et al. Molecular mechanisms of enhanced wound healing by copper oxide-impregnated dressings. *Wound Repair Regen* 2010; 18: 266-75.
- [9] Phillips N, Hwang H, Chauhan S, Leonardi D, Gonzalez S. Stimulation of cell proliferation and expression of matrixmetalloproteinase-1 and interleukin-8 genes in dermal fibroblasts by copper. *Connect Tissue Res* 2010; 51: 224-9.
- [10] Sen CK, Khanna S, Venojarvi M, et al. Copper-induced vascular endothelial growth factor expression and wound healing. *Am J Physiol Heart Circ Physiol* 2002; 282: H1821-7.
- [11] Borkow G, Gabbay J. Copper as a biocidal tool. *Curr Med Chem* 2005; 12: 2163-75.
- [12] Hostynek JJ, Maibach HI. Copper hypersensitivity: dermatologic aspects--an overview. *Rev Environ Health* 2003; 18: 153-83.
- [13] Milanino R. Copper in medicine and personal care: a historical overview. In: Hostynek TJ, Maibach HI, Eds. *Copper and the skin*. New York: Informa Health care 2006; pp. 149-60.
- [14] Borkow G, Gabbay J. Putting copper into action: copper-impregnated products with potent biocidal activities. *FASEB J* 2004; 18: 1728-30.
- [15] Borkow G, Zhou SS, Page T, Gabbay J. A novel anti-influenza copper oxide containing respiratory face mask. *PLoS ONE* 2010; 5: e11295.
- [16] Borkow G, Okon-Levy N, Gabbay J. Copper oxide impregnated wound dressings: biocidal and safety studies. *Wounds* 2010; 22: 310.

- [17] O'Brien PA, Kulier R, Helmerhorst FM, Usher-Patel M, d'Arcangues C. Copper-containing, framed intrauterine devices for contraception: a systematic review of randomized controlled trials. *Contraception* 2008; 77: 318-27.
- [18] Omae I. General aspects of tin-free antifouling paints. *Chem Rev* 2003; 103: 3431-48.
- [19] Schultz TP, Nicholas DD, Preston AF. A brief review of the past, present and future of wood preservation. *Pest Manag Sci* 2007; 63: 784-8.
- [20] Mumcuoglu KY, Gabbay J, Borkow G. Copper oxide impregnated fabrics for the control of house dust mites. *Int J Pest Manag* 2008; 54: 235-40.
- [21] Borkow G, Gabbay J, Lyakhovitsky A, Huszar M. Improvement of facial skin characteristics using copper oxide containing pillowcases: a double-blind, placebo-controlled, parallel, randomized study. *Int J Cosmet Sci* 2009; 31: 437-43.
- [22] Borkow G. Protection of Soldiers' feet by copper oxide impregnated socks. *Mil Technol* 2011; in press.
- [23] Zatzoff RC, Smith MS, Borkow G. Treatment of tinea pedis with socks containing copper-oxide impregnated fibers. *Foot (Edinb)* 2008; 18: 136-41.
- [24] Borkow G, Mellibovsky JC. Resolution of skin maladies of the trapped Chilean miners: the unplanned underground copper-impregnated antifungal socks "trial". *Arch Dermatol* 2012; 148: 134-6.
- [25] Wilcox D, Dove B, McDavid D, Greer G. ImageTool for Windows Version 3.0. The University of Texas Health Science Center 2002. Available from: <http://ddsdx.uthscsa.edu/dig/itdesc.html>.
- [26] Kaliyadan F, Manoj J, Venkitakrishnan S, Dharmaratnam AD. Basic digital photography in dermatology. *Indian J Dermatol Venereol Leprol* 2008; 74: 532-6.
- [27] Tanaka H, Nakagami G, Sanada H, *et al.* Quantitative evaluation of elderly skin based on digital image analysis. *Skin Res Technol* 2008; 14: 200.
- [28] Chivatakarn O, Kaneko S, He Z, Tessier-Lavigne M, Giger RJ. The Nogo-66 receptor NgR1 is required only for the acute growth cone-collapsing but not the chronic growth-inhibitory actions of myelin inhibitors. *J Neurosci* 2007; 27: 7117-24.
- [29] Baran R, Sparavigna A, Setaro M, Mailland F. Computerized image analysis of nails affected by fungal infection: evaluation using digital photographs and manually defined areas. *J Drugs Dermatol* 2004; 3: 489-94.
- [30] Whited JD, Hall RP, Simel DL, *et al.* Reliability and accuracy of dermatologists' clinic-based and digital image consultations. *J Am Acad Dermatol* 1999; 41: 693-702.

Received: March 19, 2012

Revised: May 02, 2012

Accepted: May 07, 2012

© Gargiulo *et al.*; Licensee *Bentham Open*.

This is an open access article licensed under the terms of the Creative Commons Attribution Non-Commercial License (<http://creativecommons.org/licenses/by-nc/3.0/>), which permits unrestricted, non-commercial use, distribution and reproduction in any medium, provided the work is properly cited.